

PATIENT

Kobe Neadle

SPECIES

Canine

BREED

Boston Terrier

SEX

MN

AGE

12yr

WEIGHT

19.5lb

INTERPRETED BY

Remo Lobetti, BVSc,
MMedVet (Med), PhD,
Dipl. ECVIM

IMAGING PERFORMED BY

Kerri Becker

HOSPITAL NAME

Northvale Vet

REFERRING VET

Dr Simon

INVOICE
25017

DATE
06/05/2026

PRESENTING CLINICAL SIGNS

Pos. hepatomegaly/ splenomegaly seen on rads- hx elev. liver enzymes.

meds- galliprant, gaba, dasaquin, ursodoil, denamarin.

Abnormal PE/Chem/CBC/UA Results: alt-287 ast-63 alp-1245 ggt-21 chol-389

ULTRASONOGRAPHIC EXAMINATION OF THE ABDOMEN

Urinary System

Small urinary bladder with a thickened and irregular appearance of the apical wall, measuring ~ 0.8 cm. Mineralization evident within the thickened area of the wall. Rest of the bladder wall is of normal thickness with a smooth appearance. Normal anechoic urine with no sediment evident. A focal urolith present, measuring ~ 0.9 cm in size.

Normal appearance of the trigone area, proximal urethra, and iliac blood vessels.

Normal appearance and size of the iliac lymph nodes. Ureters not visualized, which can be considered a normal finding.

Normal renal size, architecture, echogenic appearance, cortico-medullary differentiation, which maintains a 1:3 cortex to medulla ratio, pelvis, and capsule. No infarcts, mineralization or renoliths evident.

The left kidney measured 4.5 cm in length.

The right kidney measured 4.8 cm in length.

Small hypoechogenic prostate.

Adrenal Glands

Normal shape, echogenic appearance, size, position, and appearance of the visible peri-renal vasculature.

The left adrenal gland measured 2.12 cm x 0.59 cm x 0.91 cm.

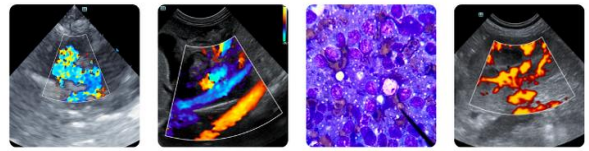
The right adrenal gland measured 1.7 cm x 0.71 cm x 0.54 cm.

Spleen

Normal size and echogenic appearance. Smooth homogenous parenchyma and regular curvilinear capsule. Normal volume of the splenic vasculature without any overt congestion or thrombosis evident. No inflammatory, neoplastic, infarction, or infiltrative changes evident. The spleen measured 1.2 cm in width.

Liver

Normal size with a diffuse increased echogenic and coarse appearance. Normal portal markings and irregular curvilinear capsule. Focal hypoechogenic parenchymal nodule in the left lobe measuring ~ 1 cm x 1.17 cm in size. No additional nodules or masses evident. Normal appearance of the hepatic and portal vasculature.



PATIENT

Gallbladder

Kobe Neadle

Full containing normal anechoic bile. Normal thickness and echogenic appearance of the wall. Normal size and appearance of the cystic and common bile duct.

SPECIES

Gastrointestinal

Canine

Normal appearance of the stomach, duodenum, small intestine, ileo-cecal junction, and colon with no loss of layering, 1:3 muscularis to mucosa ratio, normal wall thickness and peristaltic activity, and no distension of the lumen. Moderate amount of gas present within the stomach.

BREED

Pancreas

Boston Terrier

Normal size and echogenic appearance. Regular capsule. Normal echogenic appearance of the mesentery and fat surrounding the pancreas.

SEX

Free Abdomen

MN

Normal mesenteric lymph nodes.

AGE

No ascites evident.

12yr

ULTRASONOGRAPHIC FINDINGS

WEIGHT

19.5lb

- Hepatopathy
- Hepatic nodule
- Urinary bladder thickening
- Urolith

INTERPRETATION OF THE FINDINGS & FURTHER RECOMMENDATIONS

INTERPRETED BY

Remo Lobetti, BVSc,
MMedVet (Med), PhD,
Dipl. ECVIM

Etiologies for the hepatopathy would be reactive hyperplasia, nodular hyperplasia, vacuolar, metabolic and drug-induced with hepatitis and infiltrative neoplasia unlikely differential diagnoses. The most likely etiology for the hepatic nodule would be nodular hyperplasia. The most likely etiology for the urinary bladder thickening would be secondary to the urolith with chronic bacterial cystitis, a possible differential diagnosis and emerging neoplasia, a less likely differential diagnosis.

IMAGING PERFORMED BY

Kerri Becker

Further assessment would be UA, urine culture and possibly BRAF analysis and /or a catheter assisted aspirate / biopsy of the urinary bladder wall for cytology/ histopathology and culture. FNA cytology of the liver could also be considered, however a true cut or wedge biopsy may be required for a final etiological diagnosis.

HOSPITAL NAME

Northvale Vet

Specific therapy would be dependent on an etiological diagnosis. Symptomatic management would be to continue with the current therapy.

REFERRING VET

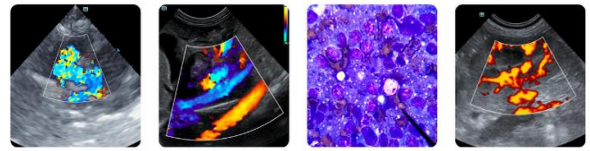
Dr Simon

INVOICE

25017

DATE

06/05/2026



PATIENT

Kobe Neadle

SPECIES

Canine

BREED

Boston Terrier

SEX

MN

AGE

12yr

WEIGHT

19.5lb

INTERPRETED BY

Remo Lobetti, BVSc,
 MMedVet (Med), PhD,
 Dipl. ECVIM

IMAGING PERFORMED BY

Kerri Becker

HOSPITAL NAME

Northvale Vet

REFERRING VET

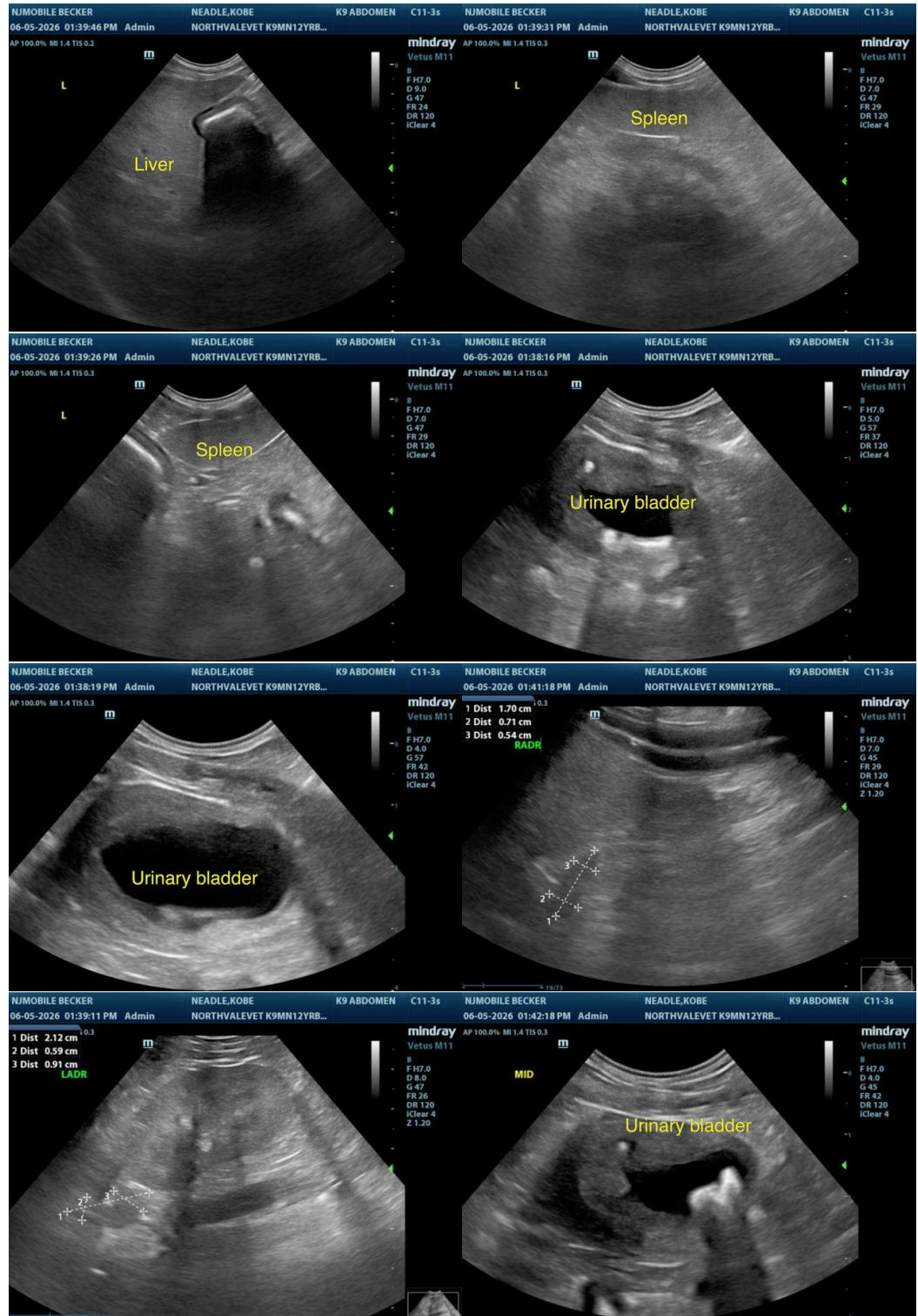
Dr Simon

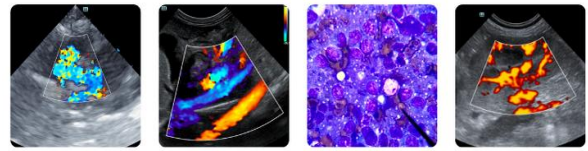
INVOICE

25017

DATE

06/05/2026





PATIENT

Kobe Neadle

SPECIES

Canine

BREED

Boston Terrier

SEX

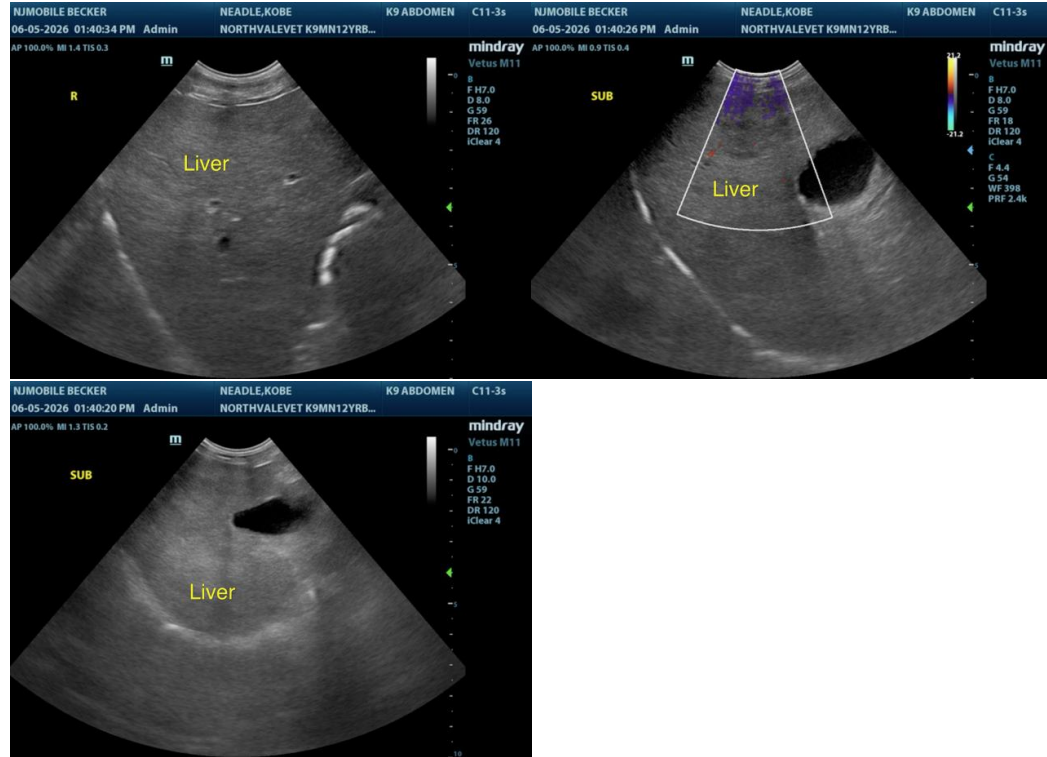
MN

AGE

12yr

WEIGHT

19.5lb



INTERPRETED BY

Remo Lobetti, BVSc, MMedVet (Med), PhD, Dipl. ECVIM

The information and recommendations provided are based on the images presented by the referring veterinarian. No evaluation can be communicated regarding pathology that was not visible in the image/video clips provided.

Thank you for this referral. If the clinical or image interpretation does not parallel your findings or if I can be of any further assistance, please contact me.

IMAGING PERFORMED BY

Kerri Becker

Remo Lobetti, BVSc, MMedVet (Med), PhD, Dipl. ECVIM (Internal Medicine)

HOSPITAL NAME

Northvale Vet

info@sonopath.com

REFERRING VET

Dr Simon

INVOICE

25017

DATE

06/05/2026